

Chullin – Simanim

פרק ג – אלו טרפות

דף 46 – דף

1. *Machlokes* whether an animal is a tereifah if a small amount of the liver remains

The Mishnah taught that if *the liver was removed and nothing remains from it*, the animal is a tereifah. This implies that if any does remain, even less than a kezayis, it is kosher. This contradicts a Mishnah on Daf 54a, which states that it is kosher if a kezayis of the liver remains! Rav Yosef answers that this reflects a *machlokes*: Rebbe Chiya *would throw away* [an animal's liver], and did not consider it healthful, because he considered it a less vital (and thus less nutritious) organ. Therefore, he holds that an animal can survive with even less than a kezayis of the liver. In contrast, Rebbe Shimon bar Rebbe *would dip it* and eat it, considering it a more vital (and thus more nutritious) organ. Therefore, he requires a kezayis of the liver to remain. A *siman* to remember their positions is *the wealthy are thrifty* (i.e., Rebbe Shimon bar Rebbe, who was wealthy, would not discard the liver). Amoraim argue if this remaining kezayis of the liver must be *at the place where the liver is attached to the gallbladder*, or *in the place where it lives* (i.e., where it is attached under the kidney). Therefore, Rav Pappa requires a kezayis in both locations.

2. Examining *ri'ah da'usha* – a lung which makes a hissing noise

The Mishnah taught that *a lung which is punctured* makes the animal a tereifah. The Gemara says that if only the outer membrane is punctured, *the lower membrane protects* the lung and the animal is kosher, because Rabbah said that even a lung found without any outer membrane is kosher. If only the inner membrane is punctured, Rav Acha and Ravina argue if the outer membrane can protect the lung, and the *halachah* is that it does protect the lung. This is based on Rav Yosef's ruling about *ri'ah da'usha* – a lung which makes a hissing noise. If the source of the noise is known, we place on it a feather, spittle, or straw. *if it bubbles*, it is a tereifah (because air is escaping), and if not, it is kosher. If the source of the noise is unknown, we bring a basin of lukewarm water, *and we inflate* [the lung]. If it bubbles, it is a tereifah (because the outer membrane must also be punctured), but if not, it is kosher, because only the inner membrane is punctured, and not the outer membrane.

3. *ri'ah shibsha* מקצתה

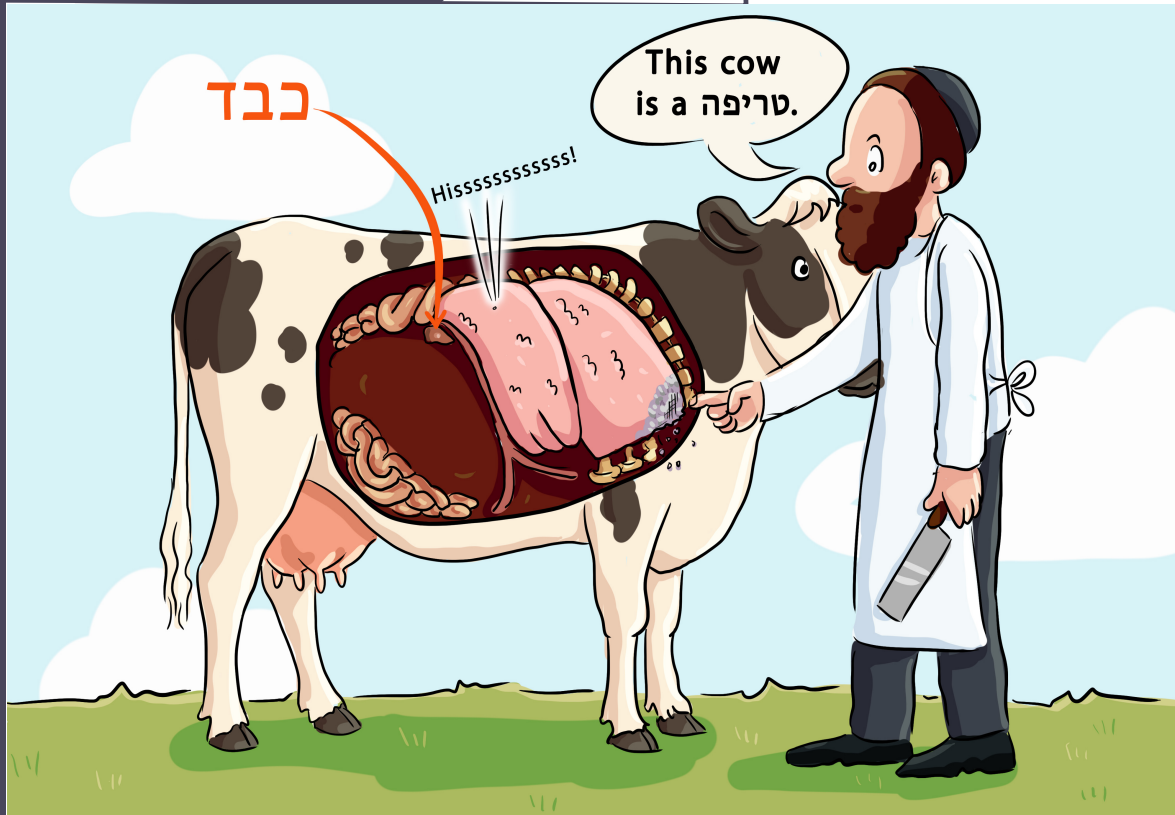
Rava said: *ri'ah shibsha* מקצתה – a lung which dried up partially is a tereifah. Rav Pappa quoted him defining this as *so that it crumbles when pressed with a fingernail*. The Gemara asks if this definition only follows one Tanna's opinion, because in a Baraisa defining what is considered "dried up" regarding the ear of a *bechor*, the Tanna Kamma says: *that when [the ear is] pierced, it does not emit a drop of blood*, but Rebbe Yose ben Meshulam says it has dried to the point that it crumbles when pressed with a fingernail. Apparently, Rava's ruling follows this latter opinion. The Gemara answers that the Rabbonon may agree with Rava. Regarding the ear of a *bechor*, *where the air impacts it*, *it will not return to health*, and a lesser degree of drying is considered "dried out." In contrast, the lung, which is not exposed to the air, can return to health, and is not considered "dried out" unless it is dry to the point of crumbling under a fingernail.

Siman – Cow (Moo)

The **cow** that survived with a tiny liver smaller than a *kezayis* and started making hissing noises from its lung, was determined to be a *tereifah* when the dry part of the lung started to crumble under the *shochet's* fingernail.

דף מו | DAF 46

Cow (Moo)



The cow that survived with a tiny liver smaller than a kezayis and started making hissing noises from its lung, was determined to be a tereifah when the dry part of the lung started to crumble under the shochet's fingernail.

3 things to remember

1. *Machlokes* whether an animal is a tereifah if a small amount of the liver remains
2. Examining ריאה דאוּוּשָׁא – a lung which makes a hissing noise
3. ריאה שיבשה מקצתה

